

# CLEFT LIP & PALATE – BASIC CARE

Dr. Kevin Robertson, Foundation Oral Surgery,  
Alberta Children's Hospital

## FOREWORD

The Alberta Society of Dental Specialists (ASDS) is the official group that represents all Dental Specialists in the Province of Alberta. There are now 10 nationally recognized dental specialties. In every edition of the ADA Connection going forward, you'll see an article from one of our members on a topic of interest to the dental community.

The information here should not be relied on for clinical decision making and does not necessarily reflect the views of the ASDS or ADA. For more information or to join our organization, visit our website at [www.asds.ca](http://www.asds.ca). If you're a specialist member in ASDS and you're interested in submitting an article for a future ADA Connection, please contact us at [asdsinformation@gmail.com](mailto:asdsinformation@gmail.com).

**Dr. Kevin Robertson**  
ASDS President  
Oral and Maxillofacial Surgeon

**Cleft lip and palate is more common than most people think, affecting approximately 1 in 700 live births. With approximately 50,000 births in Alberta per year, this amounts to about 71 affected children every year (in addition to cases acquired via immigration to Canada). These children are treated in either Calgary (Alberta Children's Hospital) or Edmonton (Stollery Children's Hospital).**

The cleft can involve the palate (37%), the lip (23%), or both (40%). The severity of cleft conditions varies considerably, and no two clefts are exactly alike. It is extremely common for teeth in the area of a cleft to be missing or malformed (most commonly lateral incisors), and some patients have supernumerary teeth. Interestingly, this is also common for the non-cleft side in unilateral cases.

While cleft is not genetic per se, there can be a genetic predisposition. If one parent has a cleft, the risk to the child is 2-8% (can be higher if a specific gene or syndrome is involved). If 1 sibling has a cleft the risk to the next child is 4%, and if 2 siblings are affected, the third child's risk is 9%. In the majority of

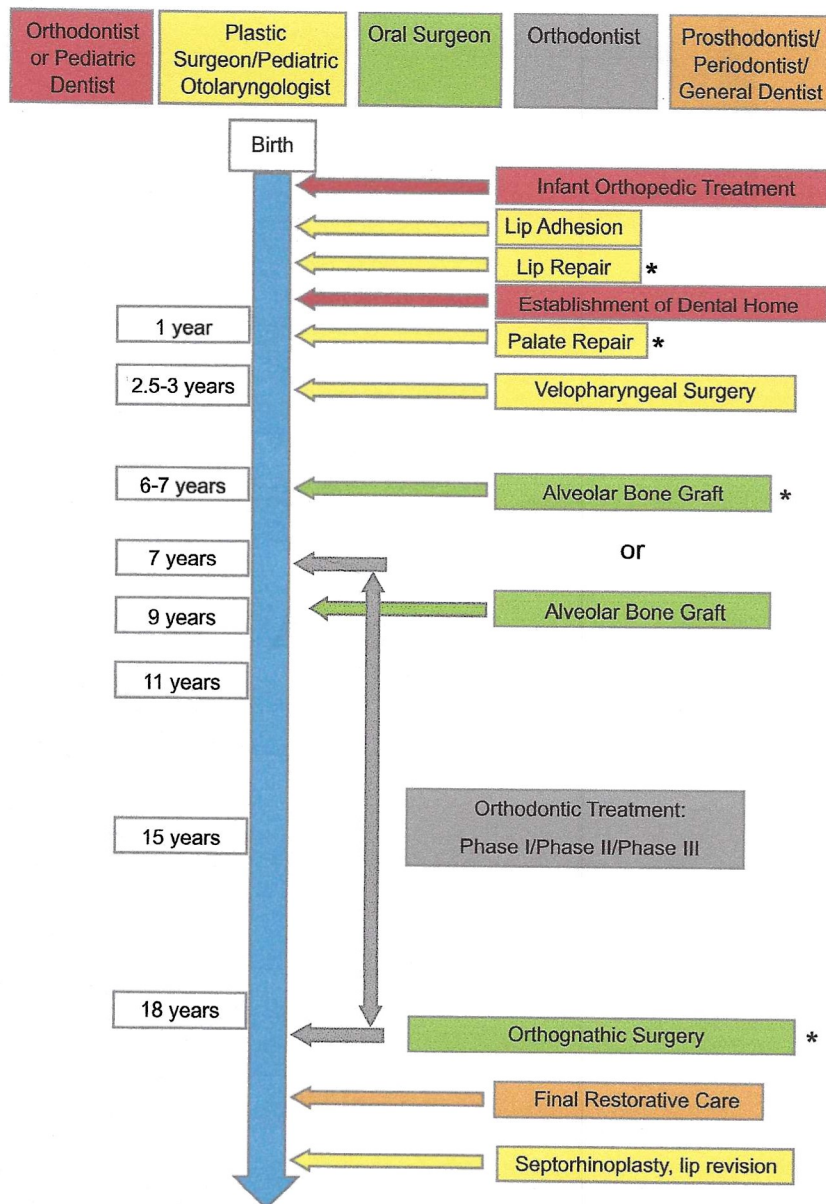
general cleft cases (86%) the child does NOT have an associated syndrome.

Treatment of these children in the hospital setting is a multidisciplinary effort as there are many complex issues going on. Some of the specialists closely involved in cleft care in the hospital include (in alphabetical order): Oral and Maxillofacial Surgery, Orthodontics, Otolaryngology, Pediatric Dentistry, Pediatric Medical Doctors, Plastic and Reconstructive Surgery, and Speech-Language Pathology. Once these children are older, even more dentists and dental specialists become involved in their outpatient care.

Figure 1 outlines the general cleft pathway for most interventions for children with clefts. The four "core" surgeries (marked \*) include lip repair, palate repair, alveolar bone grafting, and orthognathic (jaw) surgery. While every child is treated according to their particular needs, these are the primary interventions required of most children with cleft lip and palate. In addition to these procedures, additional revision procedures are sometimes required, so the surgical burden on these



**Figure 1**



patients is not insignificant. My discussion below will focus on secondary cleft care (from alveolar bone grafting and onwards) as it has more implications for the dental field.

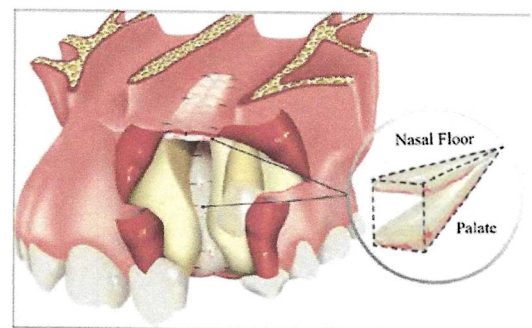
Timing of alveolar bone grafting is a topic of some controversy, but typically in Alberta our preference is to treat these children at 6-7 years old unless they require a specific orthodontic intervention first (such as maxillary expansion or positioning of the premaxilla). If

this procedure is done later in life we typically see worse bone and periodontal outcomes, although sometimes circumstances require it (for example, patients with developmental delays or immigrants from countries with limited access to primary or secondary cleft care).

The bone graft is most commonly taken from the patient's anterior iliac crest, although alternative approaches are gaining popularity. The purpose of the bone graft is fourfold: it (i) provides continuity

of the alveolar ridge; (ii) ensures adequate bone for tooth eruption or orthodontic tooth movement through the area or later dental implants; (iii) establishes appropriate bone support for the alar base and nasal floor; and (iv) closure of any remaining oro-nasal fistulas. See figure 2 for a diagram of the alveolar cleft defect to be reconstructed once it has been exposed.

**Figure 2**



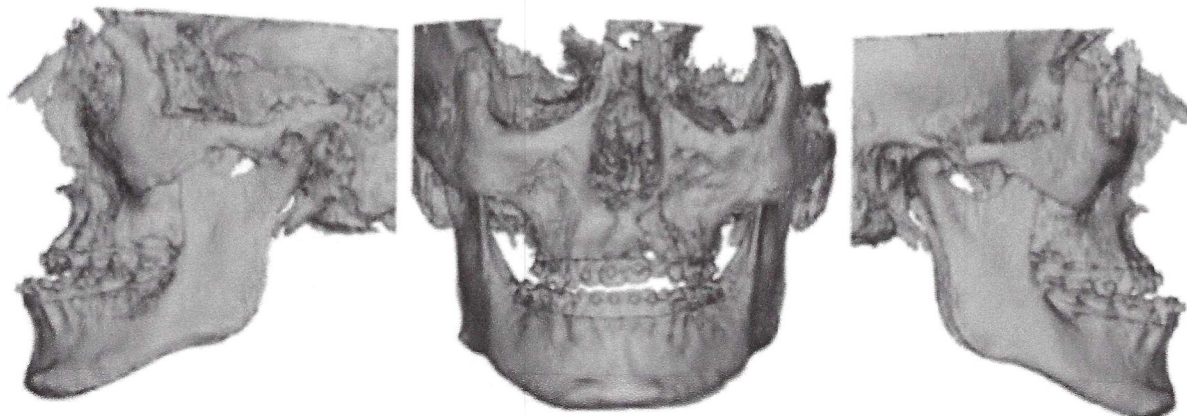
The literature is quite variable on the incidence of orthognathic surgery in cleft lip and palate patients, as it is site specific depending on surgical protocols, availability of orthopedic treatment, and tolerance for orthodontic camouflage or malocclusion. Studies suggest the percentage of all cleft patients that require orthognathic surgery is approximately 50%, but this also depends on the severity of the cleft - it is as high as 76% in bilateral complete cleft lip and palate and as low as 23% in unilateral incomplete cleft lip and palate. In our centers our experience is that approximately 30% of all patients require orthognathic surgery to provide them with a functional and stable occlusion.

Figure 3 shows a patient with unilateral complete cleft lip and palate with quite severe maxillary hypoplasia requiring a large segmental advancement. Orthognathic surgery has become increasingly common for correction of skeletal malocclusions - in Alberta it is performed almost daily - and it is well tolerated with

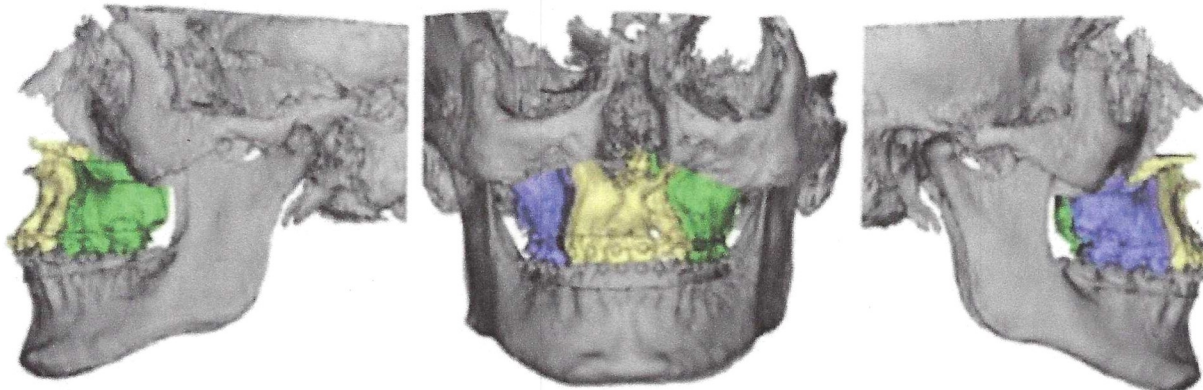


Figure 3

### Preoperative Position



### Postoperative Position



improved techniques, including advances in fixation.

In some cases, distraction osteogenesis of the maxilla is required for a stable and predictable advancement, particularly if there is associated midfacial deficiency (such as in Crouzon Syndrome) or is the required maxillary advancement is more than 10-12mm. Additionally, in Alberta, generally all cleft patients for LeFort I advancement are treated with a custom plate (called a "patient-specific implant"), which reduces the relapse associated with

these difficult cases.

At skeletal maturity and following orthognathic surgery (if necessary), patients often require dental implants to replace missing or malformed teeth. Even in patients with previous alveolar bone grafting, approximately 25% of these patients require additional bone grafting for implants. The prosthodontic work at the end of these cases is typically also complex due to skeletal relapse, abnormal lip anatomy, bony deficiencies, and significant AP changes, so these cases are mostly

completed by prosthodontists. Once this prosthodontic treatment is all complete, patients can then be considered for revisions of the lip and/or nose with plastic and reconstructive surgery.

Patients very often require extensive orthodontic treatment (often involving up to 3 different periods of treatment) regardless of whether orthognathic surgery is required, so general hygiene and teeth maintenance is crucial throughout care. The scope of the complex orthodontic treatment required

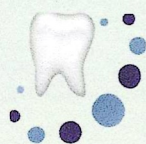

for these patients is beyond the scope of this article, but should generally be done only by orthodontists with significant experience with cleft lip and palate patients.

Also critical is communication between team members "inside" cleft clinic with our colleagues providing care "outside" clinic. We do our best to send correspondence from cleft clinic to orthodontists or pediatric dentists involved in patient care when relevant updates are required. If you have cleft patients under your care being seen in the Calgary cleft clinic, letters, radiographs, or questions that you would like addressed can be sent to [achcleftpalateclinic@ahs.ca](mailto:achcleftpalateclinic@ahs.ca) or fax 403-476-7769. For the Edmonton cleft clinic, these can be sent to fax 780-407-7744 or [Shelly.Leeb@albertahealthservices.ca](mailto:Shelly.Leeb@albertahealthservices.ca). The Oral and Maxillofacial Surgeons in cleft clinic have generally undergone an additional fellowship year following OMFS residency training, and they include Dr. Matt Fay and Dr. Kevin Lung in Edmonton, and Dr. Miller Smith and I (Dr. Kevin Robertson) in Calgary. The orthodontist in clinic in Edmonton is Dr. Evelyn Diduch, and the two orthodontists in clinic in Calgary are Dr. Jennifer Smith and Dr. Catherine Cho.

There is a funding program available to cover out of pocket dental costs for treatment of these patients. It covers Albertans under the age of 25 who have a congenital cleft involving the alveolus, or a cleft of the hard palate with orthodontic implications (such as class III malocclusion or missing teeth). This program covers orthodontic treatment, dental implants, implant crowns, fixed bridges, some perio surgery, and even some restorative treatment within 2 teeth of the cleft site. Patients over the age of 25 can sometime be approved for funding on a case by case basis. Please contact Denise Buckler-McCulloch at [Denise.Buckler-McColloch@albertahealthservices.ca](mailto:Denise.Buckler-McColloch@albertahealthservices.ca) to inquire about funding if you have a patient that fits the above criteria.

Care of these patients can be challenging but is very rewarding, and we are grateful to the extensive network of providers we work with throughout Alberta who are so dedicated to providing the highest level of cleft care available anywhere.



**EDMONTON**  
DIAGNOSTIC IMAGING INC.  
ORAL & MAXILLOFACIAL RADIOLOGY

## Do You Need CBCT Imaging and Reporting Services?

**WE HAVE A SOLUTION FOR YOU!**

### Advanced Dental Imaging Services

#### CBCT SCANS

Implant Planning with Surgical Guide STL Files  
Temporomandibular Joints  
Pathological Investigations  
Impactions / Supernumeraries  
Sinus/Airway Analysis  
Orthodontic  
High Resolution Small to Large Scans

#### OMR REPORTS

Comprehensive CBCT Interpretation  
Rule out Pathology in CBCT's  
Conventional Radiographs

#### ORTHODONTIC RECORDS

Cephalometric & Computerized Analyses  
Panoramic  
Digital Impressions & STL files  
Diagnostic Digital Photographs

**Oral & Maxillofacial Radiologists  
Registered in Alberta**

EXTRACTING CLINICAL VALUE FROM YOUR SCANS

CBCT ACQUISITION

INTERPRETATION REPORTS FOR YOUR SCANS



ScanMe!

Connect with us:

f Edi Edmonton

@edimaging

+1 780 483-1338 [www.edxi.com](http://www.edxi.com)

6643-177 Street, Callingwood Square  
Edmonton, Alberta, Canada T5T 4K3